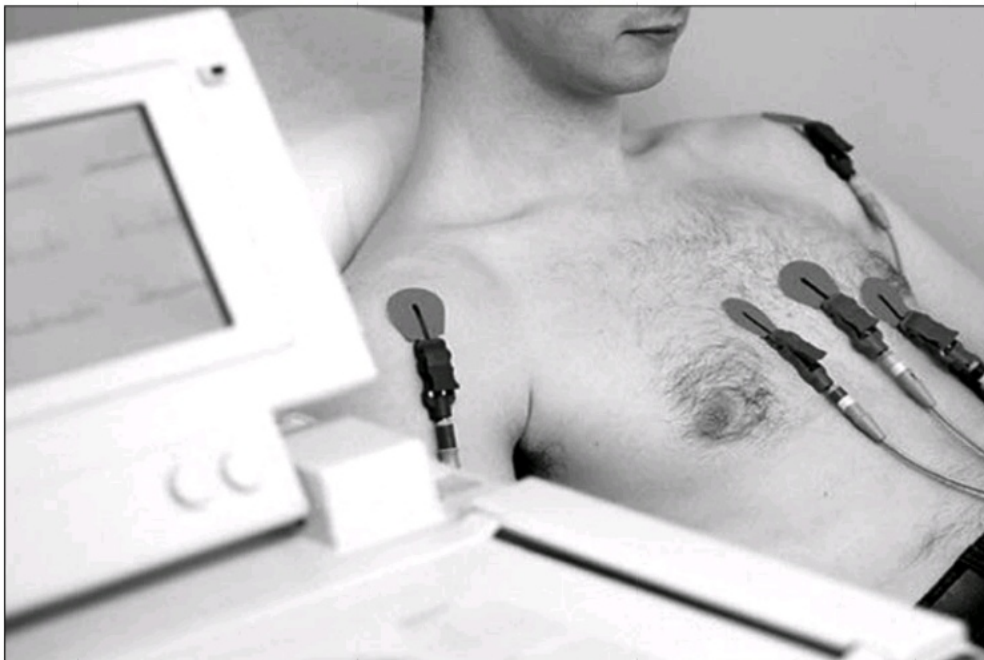

Chapter 2

Electrocardiogram (ECG or EKG)



An electrocardiogram (ECG or EKG) is a recording of the electrical activity of the heart over time, usually in a noninvasive recording via skin electrodes

Section I: Before you read

A. Key words:

Attempt understanding the meaning of the new words in the following sentences.

- invasive(adj.)** some diseases such as cancer are **invasive** and can spread within the body very quickly.
- etymology(n.)** The study of the origin and history of words and their meanings are subject matter of **etymology**.
- trace(v.)** The police **traced** the call to her number to find out who made the telephone call.
- derive(v.)** The new drug is **derived** from saffron.
- intimate(adj.)** An **intimate** knowledge of English is needed for this job.
- stimulate(v.)** The article can be used to **stimulate** discussion among the students.
- induce(v.)** You should avoid taking drugs which **induce** sleep.
- infraction(n.)** There are some minor **infractions** of the export regulations.
- composite(n.)** The document was a **composite** of information from various sources
- augment(v.)** The Iranian exportation has been **augmented** in the recent years.

B. Word Building: Using prefixes; im , non, uni, bi, myo
you can change the meaning of many adjectives/nouns by adding a prefix.

prefix	meaning	examples
im-	Not, the opposite of	impossible, imperfect
non-	not	Noninvasive, nonalcoholic, nonfiction
uni-	one,	uniform, unity, unit un-Iranian activities
bi-	two	bicycle, bilingual, bilateral
myo-	muscle	myocardial, myodynia

C. Think about the following questions and then attempt answering them.

1. What is an ECG?
2. What does a typical ECG consist of?
3. What do electrical impulses do?
4. What are the roles of electrodes in ECG?
5. What are ECG leads? And What do they do?

Section II: Reading

Electrocardiogram

- 1 An **electrocardiogram** (ECG or EKG) is a recording of the electrical activity of the heart over time, usually in a noninvasive recording via skin electrodes. The etymology of the word ECG is derived from electro, because it is related to electrical activity, cardio, Greek for heart, gram, a Greek root meaning “to write”. A typical ECG tracing of a normal heartbeat (or cardiac cycle) consists of a P wave, a QRS complex and a T wave (Figure 2-1).

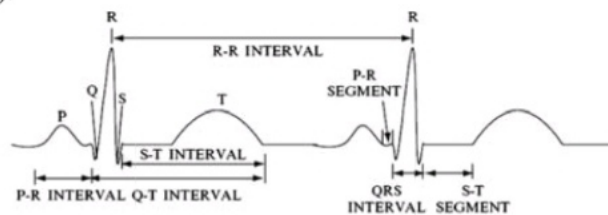


Figure 2-1. This electrocardiogram is typical of one that would be recorded from the body's surface by having a positive electrode on the left leg and a negative electrode on the right arm. The vertical direction represents voltage and the horizontal direction represents time. The P, R, and T waves are easily identified and are the result of the movement of ions in cells in different parts of the heart. Different intervals and segments have been identified which provide information about the health of the heart and its conduction system. The R-R interval can be used to determine heart rate. (John D. Enderle, Susan M. Blanchard, Joseph D. Bronzino, *Introduction to biomedical engineering*, p. 98)

- 2 Electrical impulses in the heart originate in the senatorial node (SA node) and travel through the intimate conducting system to the heart muscle. The impulses stimulate the myocardial muscle fibers to contract and finally induce systole. Electrodes on different sides of the heart measure the activity of different parts of the heart muscle. An ECG displays the voltage between pairs of these electrodes, and the muscle activity that they measure, from different directions, are also understood as vectors. This display indicates the overall rhythm of the heart and weaknesses in different parts of the heart muscle. It is the best way to measure and diagnose abnormal rhythms of the heart, particularly abnormal rhythms caused by electrolyte imbalances. In a myocardial infarction (MI), the ECG can identify when the heart muscle has been damaged in specific areas, though, not all areas of the heart are included. The ECG cannot reliably measure the pumping ability of the heart, for which, ultrasound-based (echocardiography) or nuclear medicine tests are used.

- 3 An electrocardiogram is obtained by measuring electrical potential between various points of the body using a biomedical instrumentation amplifier. The ECG leads record the electrical signals of the heart from a particular combination of recording electrodes which are placed at specific points on the patient's body.
- 4 There are two types of leads— bipolar and unipolar. Bipolar leads have one positive and one negative pole. In a 12-lead ECG, the limb leads (I, II and III) are bipolar leads. Unipolar leads have only one pole (the positive pole). The negative pole is a “composite” pole made up of signals from lots of other electrodes. In a 12-lead ECG, all leads besides the limb leads are unipolar (aVR, aVL, aVF, V1, V2, V3, V4, V5, and V6).
- 5 In both the 5- and 12-lead configuration, leads I, II and III are called limb leads. The electrodes that form these signals are located on the limbs—one on each arm and one on the left leg. The limb leads form the points of what is known as Einthoven's triangle.
 - Lead I is the signal between the (negative) RA electrode (on the right arm) and the (positive) LA electrode (on the left arm).
 - Lead II is the signal between the (negative) RA electrode (on the right arm) and the (positive) LL electrode (on the left leg).
 - Lead III is the signal between the (negative) LA electrode (on the left arm) and the (positive) LL electrode (on the left leg).

• Leads aVR, aVL, and aVF are ‘augmented limb leads’. They are derived from the same three electrodes as leads I, II, and III. However, they view the heart from different angles (or vectors) because the negative electrode for these leads is a modification of ‘Wilson's central terminal’, which is derived by adding leads I, II, and III all together and plugging them into the negative terminal of the ECG machine.(Figure 2-2)

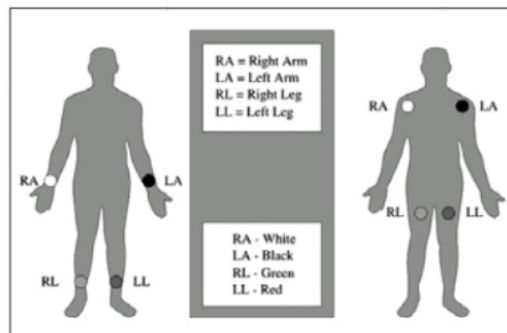


Figure2-2. Proper placement of the limb electrodes

- Lead aVR or “augmented vector right” has the positive electrode (white) on the right arm. The negative electrode is a combination of the left arm (black) electrode and the left leg (red) electrode, which “augments” the signal strength of the positive electrode on the right arm.
- Lead aVL or “augmented vector left” has the positive (black) electrode on the left arm. The negative electrode is a combination of the right arm (white) electrode and the left leg (red) electrode, which “augments” the signal strength of the positive electrode on the left arm.
- Lead aVF or “augmented vector foot” has the positive (red) electrode on the left leg. The negative electrode is a combination of the right arm (white) electrode and the left arm (black) electrode, which “augments” the signal of the positive electrode on the left leg.

Edward J. Barbari (2006), Andrew R. Houghton (2008)

Section III: After you read**A. Comprehension activities**

a. Read the statements below and write T for true and F for false statements. Then justify your option by writing the number of paragraph in the passage that helped you.

1. ----/---- EKG is a recording of the electrical activity of the muscle over time.
2. ----/---- A Greek root meaning of Gram is to write.
3. ----/---- A typical ECG is made up of three phases.
4. ----/---- In MI, the ECG can identify if the heart muscle has been damaged in specific areas.
5. ----/---- An electrocardiogram is obtained by measuring electrical potential between various points of the body using a myocardial instrumentation amplifier.
6. ----/---- Unipolar leads have only one positive pole.

b. Analyze the following statements and mark the best choice that completes each statement.

1. In the first paragraph, ECG is
 - a. defined and explained the origin of it.
 - b. explained in details.
 - c. displayed as a typical normal cardiac cycle.
 - d. displayed as an electrical activity occurred in a the heart.

2. An electrocardiogram is a recording of the electrical activity of the heart over time, usually in a recording via skin electrodes.
 - a. aggressive
 - b. sinatorial
 - c. normal
 - d. noninvasive

3. The etymology of the word ECG word is derived from electro, cardio, and gram meaning in Greek root respectively
 - a. electricity, heart, device
 - b. electrical activity, heart, to write
 - c. generator, cardio, diagram
 - d. electrical signal, heart, to record
4. Electrical impulses stimulate the myocardial muscle fibers to contract and thussystole.
 - a. cause
 - b. occur
 - c. induct
 - d. recognize

5. Which of the following statements is not correct about ECG?
 - a. A typical ECG is a normal heartbeat consisting of three waves
 - b. It displays the voltage between pairs of electrodes and the muscle activity
 - c. It indicates the overall rhythm of the heart and weaknesses in different parts of the heart muscle
 - d. It can reliably measure the pumping ability of the heart

6. The ECG, in a myocardial....., can identify the damaged muscles in specific areas of the heart.
a. infarction b. infection c. inefficiency d. inactivity
7. A biomedical is used to
a. obtain an electrocardiogram. b. measure electrical potential differences.
c. find myocardial problems. d. record electrical signals .
8. Bipolar and unipolar leads havein common.
a. one true pole b. one negative pole
c. both negative and positive poles d. none

c. Discussing the reading. Work in pair or group to answer the following questions.

1. What kind of information can we get from an ECG?
2. What does a typical ECG made up of ?
3. What does an ECG display?
4. How can an ECG be obtained?
5. What is Einthoven's triangle?

B. Vocabulary practices

a. Scan the paragraphs and find words with the following meanings. Numbers indicate the corresponding paragraph.

- a. A Greek root meaning "to write" (1)
- b. Cardiac cycle (1)
- c. Lack of balance and equality (2)
- d. To make something develop or become more active (2)
- e. To recognize sb/sth and be able to say who or what they are (2)
- f. Set up for a particular purpose (5)
- g. Determine the place of (5)
- h. The act of making some thing different (7)
- i. To connect to an outlet (8)

b. Which word in the reading the following definitions refer to?

1. The voltage between pairs of the electrodes, and the muscle activity that they measure, from different directions, also indicated as.
2. A recording of the electrical activity of the heart over time, usually in recording via skin Electrodes.
3. The leads which have one positive and one negative pole.
4. The negative pole is a kind of pole which consists of signals from lots of other electrodes.
5. Through which the ECG can identify if the heart muscle has been damaged in specific areas
6. An action potential which is carried down the motor neuron to the muscle.

c. Choose a word from the box below to complete each sentence

a.measure	b. invasive	c. via	d.conduct	e. systole
f. overall	g. diagnose	h. damages	i.derive	j. augment
k.by	l. illustrate	m. remove		

1. We need a device to..... the level of radiation in the atmosphere.
2. There is no firm treatment for advanced cancer cells.
3. There is an improvement in standards of living.
4. We will fly Tokyo china.
5. The contraction of the chambers of the heart (especially the ventricles) to drive blood into the aorta and pulmonary artery is called..... .
6. The blood test is used to a variety of diseases.
7. The new drug is..... from saffron plant.
8. Smoking seriouslyyour health..
9. Many metals can heat .
10. The recent speech of the boss tensions in the office.

d. Match the words/phrases in the column A with their synonyms / antonyms in the column B

Column A

1. cardio
- 2.add
- 3.typical
- 4.induce
- 5.display
- 6.obtain
- 7.besides
- 8.limb
- 9.modification
10. derive from

Column B

- a. heartbeat
- b. change
- c. heart
- d. subtract
- e. stimulate
- f. make visible
- g. next
- h. in addition to
- i. come from
- j.a typical
- k. an arm or a leg
- l. lose

C. Cloze exercise

Fill out the following blanks with the best word from the box bellow.

1. Transient	2. monitoring	3. heart	4. EEG	5. Epileptic	6. Identify
--------------	---------------	----------	--------	--------------	-------------

In medicine, a Holter monitor (also called an ambulatory device) is a portable device for continuouslyvarious electrical activity of the central nervous system for at least 24 hours. The most common use is for monitoring theor ECG, but can also be used for monitoring Its extended recording period is sometimes useful for observing occasional cardiac arrhythmias or events (EEG) that would be difficult toin a shorter period of time. For patients having more symptoms, a cardiac event monitor which can be worn for a month or more can be used.